Available online at www.sciencedirect.com

ScienceDirect

journal homepage: www.elsevier.com/locate/radcr

Case Report

Radiofrequency denervation and cryoablation of the lumbar zygapophysial joints in the treatment of positive lumbar facet joint syndrome – a report of three cases ☆,☆☆

Ladislav Kočan, MD, PhD[a,b], *Róbert Rapčan, MD, PhD*[c], *Rudolf Sudzina, MD, PhD*[d], *Simona Rapčanová, MD*[c], *Dušan Rybár, MD*[a], *Juraj Mláka, MD*[b], *Hana Kočanová, MD*[e], *Miroslav Buriánek, MD*[f], *Janka Vašková, PhD*[g,*]

[a] *Clinic of Anesthesiology and Intensive Care Medicine, East Slovak Institute of Cardiovascular Disease, Ondavská 8, 040 11 Košice, Slovak Republic*
[b] *EuroPainClinics, Poliklinika Terasa, Toryská 1, 040 11 Košice, Slovak Republic*
[c] *EuroPainClinics, Na hradbách 94/3, 085 01 Bardejov, Slovak Republic*
[d] *Neurological Clinic, East Slovak Institute of Cardiovascular Disease, Ondavská 8, 040 11 Košice, Slovak Republic*
[e] *Clinic of Anesthesiology and Intensive Care Medicine, Railway Hospital and Clinic Košice, Slovak Republic*
[f] *EuroPainClinics, Starochodovská 1750/91, 149 00 Prague 4, Czech Republic*
[g] *Department of Medical and Clinical Biochemistry, Faculty of Medicine, Pavol Jozef Šafárik University in Košice, Tr. SNP 1, 040 11, Košice, Slovak Republic*

ARTICLE INFO

Article history:
Received 27 July 2022
Revised 30 August 2022
Accepted 4 September 2022
Available online 26 September 2022

Keywords:
Cryoablation
Facet joint
Radiofrequency ablation
Zygapophysial joint

ABSTRACT

Radiofrequency denervation of the zygapophysial (facet) joints is a frequently performed procedure for chronic low back pain. However, cryoablation represents a novel therapeutic approach for this condition. We observed and analyzed 3 cases with confirmed positive lumbar facet joint syndrome. Our results show a significant improvement in the clinical state of the patients in the first and third months after the procedure. The 6-month follow-up examination demonstrates a recurrence of pain and a gradual deterioration in the quality of life with a lasting partial pain-relief effect. Thermal radiofrequency denervation and cryoablation of the lumbar zygapophysial joints represent an effective, albeit temporary treatment option for lumbar facet joint syndrome patients, resulting from the pathophysiology of sensory nerve regeneration after destructive procedures. This type of treatment can be used repeatedly in the case of a positive response.

© 2022 The Authors. Published by Elsevier Inc. on behalf of University of Washington. This is an open access article under the CC BY-NC-ND license (http://creativecommons.org/licenses/by-nc-nd/4.0/)

☆ Competing Interests: None of the authors has financial/commercial conflicts of interest with the published data.
☆☆ Funding: This research did not receive any specific grant from funding agencies in the public, commercial, or not-for-profit sectors.
* Corresponding author.
E-mail address: janka.vaskova@upjs.sk (J. Vašková).
https://doi.org/10.1016/j.radcr.2022.09.010
1930-0433/© 2022 The Authors. Published by Elsevier Inc. on behalf of University of Washington. This is an open access article under the CC BY-NC-ND license (http://creativecommons.org/licenses/by-nc-nd/4.0/)

Introduction

Back pain is the most common type of pain in humans. More than 80% of the global population will experience low back pain at least once in their life and it is considered chronic if it lasts 3 months or longer [1–3]. The main cause is degenerative changes of spine structures including the facet joints, which can be a potentially important source of symptoms because of the high level of mobility and load forces, especially in the lumbar area [4,5]. Treatment of facet joint syndrome is multidisciplinary, and when conservative methods are not sufficient, radiofrequency thermal ablation is performed. More recently, cryoablation has emerged as an alternative interventional treatment option of facet joint syndrome [6,7].

In the following 3 case studies, we describe the treatment of facet joint syndrome using radiofrequency thermal ablation and cryoablation techniques placing the electrodes perpendicularly and in parallel with the nerve course. Cryoablation was performed with a CRYO-S PAINLESS device with carbon dioxide (−78°C) as a working medium for 2 minutes in 2 cycles for one nerve. This device also contains an integrated neurostimulator. When proper cryoprobe position was confirmed in multiple views, the impedance was checked and followed by sensory stimulation with a current of 50 Hz and motor stimulation with a current of 2 Hz. We followed these patients before the procedure, 4 weeks, 12 weeks, and 6 months after the procedure. Measured parameters included lower back pain intensity and intensity of pain of the lower extremities based on the Numeric Rating Scale (NRS) from 0 to 10. We used quality of life questionnaires, Oswestry Disability Index (ODI), which is focused on performing everyday activities affected by lower back pain, where the score 0 means the best possible status and 100 the worst possible status. We also used the licensed EQ-5D-5L questionnaire, evaluating the quality of life through 5 dimensions: mobility, self-care, everyday activities, pain/discomfort, and anxiety/depression. Each dimension is rated by the patient from 1 to 5, where a score of 1 means the best condition and a score of 5 means the worst possible condition. The EQ-VAS (EQ visual analogue scale) describes the current health condition, where 0 means the worst possible state, and 100 means the best possible state. This clinical trial was approved by the ethical committee of the Medical Faculty of the Pavol Jozef Safarik University in Košice, with the registration number 75/EK/15, as well as being registered in the international database clinicaltrials.gov under the registration number NCT03039296. All patients signed an informed consent about the participation in the study and publishing the clinical results.

Case series

Patient 1

Seventy-one-year-old patient, pensioner, with chronic lower back pain in the lumbo-sacral area after 6 spinal surgeries in the past, currently on combined pharmacological therapy: buprenorphine transdermal patch 35 ug/h and pregabalin 75 mg twice daily. In the past, the patient had repeated caudal pressure blocks (5 in total) with minimal therapeutic effect. The first MRI (magnetic resonance imaging) examination describes a multilevel herniation of the intervertebral discs L3/L4, L4/L5, listhesis of the L5 vertebra, and multilevel bilateral facet joint arthritis. Currently, the patient is experiencing a dull pain in the lumbo-sacral area with an NRS intensity of 9/10 radiating to the lower extremities. The patient underwent bilateral test blockade of the medial branches of the dorsal ramus of the spinal nerve (DRSN) at the interventional pain management clinic, after which they described 100% pain relief lasting for 48 hours. Subsequently, the patient underwent bilateral radiofrequency denervation of the medial branches of the DRSN innervating the facet joints L3/L4, L4/L5, and L5/S1. The radiofrequency probe was placed in parallel with the anticipated anatomical course of the sensory nerve (Fig. 1).

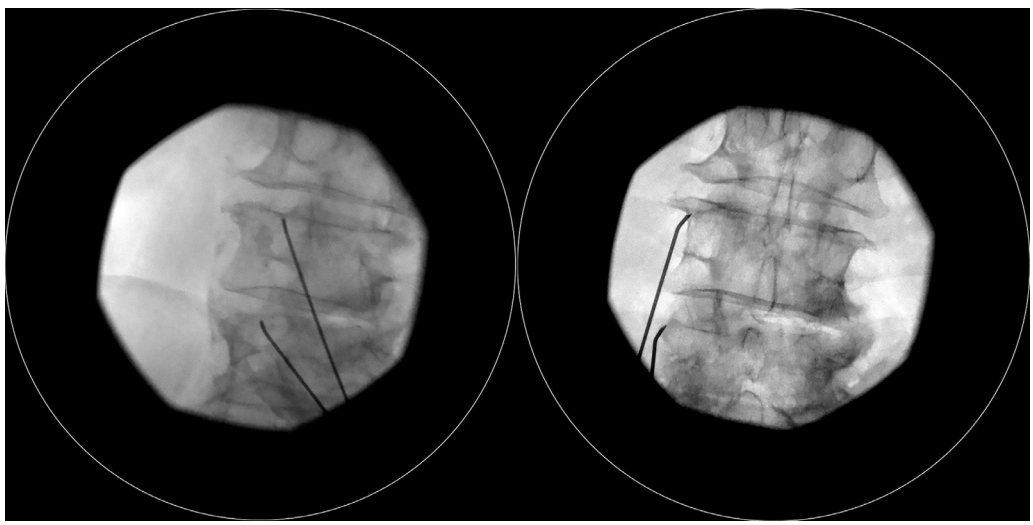

Fig. 1 – Final placement of the radiofrequency electrodes at the L3/L4 and L4/L5 facet joint level left side, anterior and oblique projections.

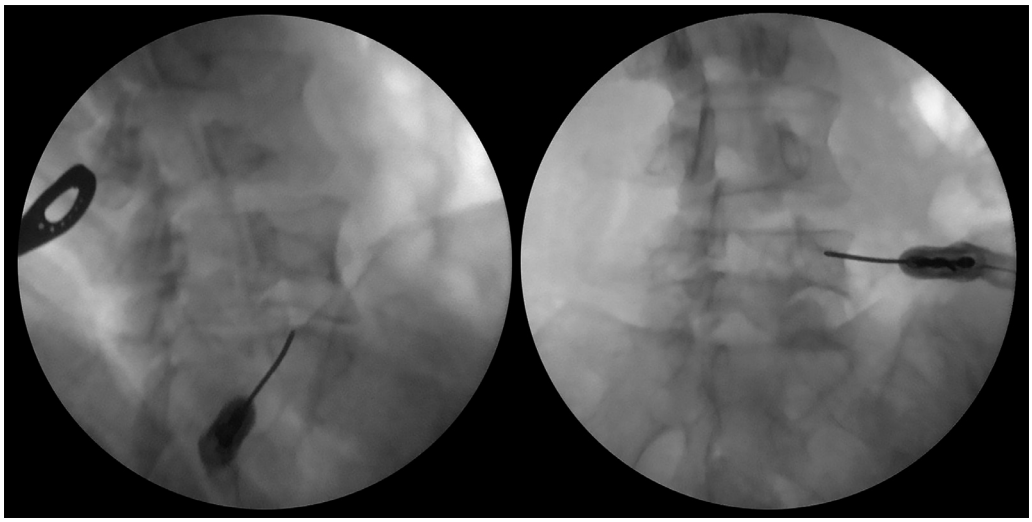

Fig. 2 – Final perpendicular placement of the cryoprobe to the L5/S1 and L4/L5 facet joints on the right, shown in the oblique projection.

Patient 2

Forty-five-year-old patient working as a teacher and artistic carpenter was repeatedly hospitalized at the neurological ward for attacks of back pain in the lumbosacral area. The current MRI of the low back spine shows multilevel discopathy, moderate ventrolisthesis of L5, minimal dorsolisthesis of L3 to L4. Further, it shows an L5/S1 intervertebral disc herniation affecting the posterior lower border of the L5 vertebra with the size 5.8 mm and a multilevel herniation. The patient has intense pain of their lumbar spine area radiating to the right lower limb, paresthesias on the lateral border of their thigh, they have problems being seated for a longer period of time. The patient has been using NSAIDs (non-steroidal anti-inflammatory drugs) in combination with Tramadol/Paracetamol tablets during intense bouts of pain. After a bilateral test blockade, the patient felt 70% relief of pain for 12 hours. They then underwent cryoablation of the medial branches of the facet joints L3/L4, L4/L5, L5/S1. The cryoprobe was placed perpendicularly to the expected anatomical course of the sensory nerve (Fig. 2).

Patient 3

Sixty-four-year-old patient with a desk job, complains of intense pain of their lumbar spine radiating to both lower limbs, more on the right, lasting approximately 4 years. The pain occurs mainly at night. The current MRI shows no compression of any structures, numerous Schmorl's nodes in vertebral bodies, L3/L4 and L4/L5 segments shows MODIC1 and MODIC2 (modic type endplate changes, status 1 and 2) changes. Clinical examination revealed pseudoradicular syndrome, provocation tests for the SI joins were negative without a sensory or motor deficit in the lower limbs. Analgesic therapy consisted of sporadic use of NSAIDs and metamizol. The patient underwent a bilateral test facet joint blockade, with significant pain relief about 90% directly after the procedure lasting up to the night hours. Here, we performed a bilateral thermal ablation of the medical branches (DRSN) L3, L4, and L5 with cryoanalgesia. The cryoprobe was placed in parallel with the expected anatomical course of the sensory nerve (Fig. 3).

In all cases, we noted a significant improvement of pain intensity in the 1st and 3rd months after the procedure with a lasting pain relief effect or slightly recurring pain at the 6 months follow-up (Table 1). Similar results were noted in patients monitored by ODI, EQ-VAS, and the EQ-5D-5 dimensions with a lasting positive treatment effect as well as a slight worsening at the 6 months follow-up (Tables 1 and 2).

Discussion

Facet joint syndrome is linked with the dysfunction in the joint of the same name, which becomes the source of pain. The most common causes of this are trauma, more commonly repeated microtrauma in the facet joint area caused by repeated extension of the lumbar spine or with overhead activities, as well as sports involving tiresome extension exercises of the lumbar spine. One of the most common causes is the damage of the intervertebral disc, which causes a disruption in the biomechanics of the facet joints. This can cause their subluxation, microtrauma, swelling of the synovium surrounding the facet joints, leading to synovitis. A hypertonic contraction of surrounding structures occurs as a defence mechanism, which leads to the worsening of pain. An important step in the diagnosis of lumbar facet joint syndrome is a test blockade of the medial branch DRSN. Precise diagnostics is important, similarly as it was performed in patients from the case series where, after injecting a small amount of local anesthetic (0.5 mL 0.5 % bupivacaine) under X-ray guidance to the sensory medial branch DRSN, significant pain relief was achieved for numerous hours. This test was performed twice in each patient. After a positive test result, cryoablation or radiofrequency denervation was performed, which provided

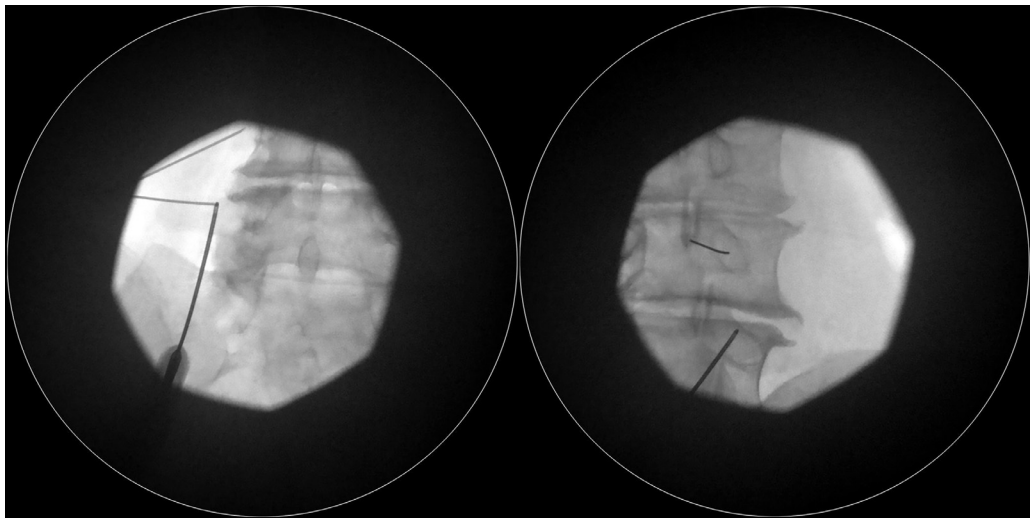

Fig. 3 – The final parallel placement of the cryoprobe to the L4/L5 facet joint on the left in the AP projection and parallel placement of the cryoprobe to the L4/L5 facet joint on the right, shown in the oblique projection.

Table 1 – Trend of change in the clinical status in the Oswestry Disability Index (ODI) and EQ-VAS (EQ visual analogue scale) parameters and pain intensity assessed by the Numerical Rating Scale (NRS) at each time interval in the lumbo-sacral back pain and pain radiating to the lower extremities followed in patients 1, 2, and 3.

Patient (number)/technical aspects	Parameters	Follow-up			
		Before procedure	1 month	3 month	6 month
Radiofrequency ablation	ODI	45	5	9	22
	EQ-VAS	50	90	80	60
	NRS back pain	9	2	1	5
	NRS leg pain	3	1	1	2
Cryoablation perpendicularly	ODI	63	31	31	45
	EQ-VAS	75	85	85	55
	NRS back pain	8	4	4	6
	NRS leg pain	8	5	5	8
Cryoablation in parallel	ODI	56	4	9	29
	EQ-VAS	55	70	85	65
	NRS back pain	7	4	2	7
	NRS leg pain	7	4	4	6

the patient with pain relief for a couple of months. Both of these procedures cause targeted physical damage of the nerve in a limited area, either by the action of an electromagnetic field, increased temperatures in the desired area, or cold temperatures. These physical effects cause reversible damage to the nerve, a so-called axonotmesis, where axonal damage occurs with the preservation of the epineurium. During this damage, a defect in the transmission of nerve signals occurs, which clinically manifests as the disappearance of pain. Distally from the nerve damage, Wallerian degeneration occurs, as well as changes of the myelin sheath, but the periphery of the nerve maintains its electrical irritability for 5-10 days. After a couple of days, the body of the neuron is activated – sprouting; each nerve fiber from the damaged axon regenerates at the speed of 1 mm per day [7,8]. The return of pain after neural ablation indicates nerve regeneration after peripheral nerve damage after a couple of weeks or months. This trend of pain recurrence was demonstrated in all patients. In clinical practice, we are also met with unsuccessful thermal ablation procedures. This can have numerous causes. The most common cause is multifactorial etiology of lower back pain. Facet joint arthropathy is often connected with discopathy, radiculopathy, spinal canal stenosis, and myofascial syndrome. The co-existence of these co-morbidities means that treating only one of them can lead to unsuccessful pain relief. Another cause can be a false positive diagnostic blockade, by injecting too much local anesthesia and its spread to the surrounding structures, which could also be the sources of pain [9–11]. A high percentage of positive reactions after a placebo dose are the cause of false positive results [12]. Aberrant nerve sprouting could also be the cause of unsuccessful treatment. Okuyama et al. discovered, that after RF ablation of the myocardium, aberrant nerve sprouting occurs already after 2 hours, and it is probable that the same process occurs after RF ablation of the medial branches of the DRSN [13,14]. The choice of facet joint thermal ablation technique (radiofre-

Table 2 – Trend of changes in the patients' assessment of everyday activities at each time interval, where a score of 5 indicates the worst possible status and the score 1 means the best possible status.

Patient/technical aspect	Mobility/ follow-up			
	Before procedure	1 month	3 month	6 month
Radiofrequency ablation	4	2	2	3
Cryoablation perpendicularly	4	2	2	3
Cryoablation in parallel	3	1	2	2
	Self-care/ follow-up			
Radiofrequency ablation	3	1	1	3
Cryoablation perpendicularly	3	2	2	3
Cryoablation in parallel	4	1	1	2
	Usual activities/follow-up			
Radiofrequency ablation	4	2	2	3
Cryoablation perpendicularly	4	2	1	3
Cryoablation in parallel	4	2	2	2
	Pain and discomfort/follow-up			
Radiofrequency ablation	4	1	2	3
Cryoablation perpendicularly	3	1	2	3
Cryoablation in parallel	4	1	2	2
	Anxiety and depression/follow-up			
Radiofrequency ablation	3	1	1	2
Cryoablation perpendicularly	3	1	2	3
Cryoablation in parallel	4	1	2	3

quency or cryoablation) as well as probe placement can also have an influence on the final treatment effect, seeing as they have different nerve damage mechanisms. The choice of interventional thermal ablation method is not strictly defined, seeing as there have been no published EBM results on the superiority of one technique over the other. In terms of the result, the shape and extent of the lesion which forms around the tip of the electrode are important, and they depend on its physical properties and treatment procedure. Placement of the RF electrode during radiofrequency denervation is defined by SIS guidelines based on EBM, which consists of placing the probe in parallel with the anatomic course of the nerve [1]. The reason is to damage the nerve the most efficiently. Placement of the cryoablation electrode is not yet clearly determined, which is why in our patients, we placed them in the 2 most common used locations in practice – perpendicular to and in parallel with the nerve course.

Conclusion

Due to the diverse etiology of lower back pain, it is imperative to determine the cause of the pain to plan the treatment procedure. To correctly determine the source of lower back pain, we have to perform a complex evaluation. In a precisely diagnosed lumbar facet joint syndrome, thermal ablation techniques represent a relevant therapeutic tool.

Patient consent

Written informed consent for the publication of this case report was obtained from each patient.

References

[1] Manchikanti L, Pampati V, Fellows B, Bakhit CE. Prevalence of lumbar facet joint pain in chronic low back pain. Pain Phys 1999;2(3):59–64.

[2] Bogduk N. Practice guidelines for spinal diagnostic and treatment procedures. San Francisco: International Spine Intervention Society, United States; 2013. p. 684. (in Eng.).

[3] Geraci MC, Baker RM, Sasso RC. Lumbar zygapophysial joint evaluation and treatment. Curr Concepts 2005:10–17.

[4] Lau P, Mercer S, Govind J, Bogduk N. The surgical anatomy of lumbar medial branch neurotomy (facet denervation). Pain Med 2004;5(3):289–98. doi:10.1111/j.1526-4637.2004.04042.x.

[5] Manchikanti L, Boswell MV, Singh V, Derby R, Fellows B, Falco FJ, et al. Comprehensive review of neurophysiologic basis and diagnostic interventions in managing chronic spinal pain. Pain Phys 2009;12(4):E71–120. doi:10.36076/ppj.2009/12/E121.

[6] Venglarčík M, Mláka J, Griger M, Tirpák R, Vinklerová V, Kočan L, et al. Radiofrequency denervation of facet joints in low back pain therapy at lumbar facet syndrome. Neurol praxi 2017;18(1):38–42 (in Slovak). doi:10.36290/neu.2017.061.

[7] Perolat R, Kastler A, Nicot B, Pellat JM, Tahon F, Attye A, et al. Facet joint syndrome: from diagnosis to interventional management. Insights Imaging 2018;9(5):773–89. doi:10.1007/s13244-018-0638-x.

[8] Menorca RM, Fussell TS, Elfar JC. Nerve physiology: mechanisms of injury and recovery. Hand Clin 2013;29(3):317–30. doi:10.1016/j.hcl.2013.04.002.

[9] Dreyfuss P, Halbrook B, Pauza K, Joshi A, McLarty J, Bogduk N. Efficacy and validity of radiofrequency neurotomy for chronic lumbar zygapophysial joint pain. Spine (Phila Pa 1976) 2000;25(10):1270–7. doi:10.1097/00007632-200005150-00012.

[10] Schwarzer AC, Wang SC, Bogduk N, McNaught PJ, Laurent R. Prevalence and clinical features of lumbar zygapophysial joint pain: a study in an Australian population with chronic

low back pain. Ann Rheum Dis 1995;54(2):100–6. doi:10.1136/ard.54.2.100.
[11] Cohen SP, Strassels SA, Kurihara C, Forsythe A, Buckenmaier CC 3rd, McLean B, et al. Randomized study assessing the accuracy of cervical facet joint nerve (medial branch) blocks using different injectate volumes. Anesthesiology 2010;112(1):144–52. doi:10.1097/ALN.0b013e3181c38a82.
[12] Lord SM, Barnsley L, Bogduk N. The utility of comparative local anesthetic blocks versus placebo-controlled blocks for the diagnosis of cervical zygapophysial joint pain. Clin J Pain 1995;11(3):208–13. doi:10.1097/00002508-199509000-00008.
[13] Okuyama Y, Pak HN, Miyauchi Y, Liu YB, Chou CC, Hayashi H, et al. Nerve sprouting induced by radiofrequency catheter ablation in dogs. Heart Rhythm 2004;1(6):712–17. doi:10.1016/j.hrthm.2004.09.012.
[14] Kim MH, Kim SW, Ju CI, Chae KH, Kim DM. Effectiveness of repeated radiofrequency neurotomy for facet joint syndrome after microscopic discectomy. Korean J Spine 2014;11(4):232–4. doi:10.14245/kjs.2014.11.4.232.